

# THE USE OF HYPNOSIS AS AN ADJUNCT TO NITROUS OXIDE/OXYGEN SEDATION: A CASE SERIES

**Abang Ibrahim DF<sup>1,2</sup>, Ismail N<sup>2</sup>, Zainal Abidin Z<sup>2</sup>, Zainuren ZA<sup>2</sup>, Harun MZ<sup>2</sup>, Venkiteswaran A<sup>2</sup>, and Abdul Halim R<sup>2</sup>.**

<sup>1</sup>Paediatric Dental Specialist Clinic, Sarawak General Hospital, Ministry of Health Malaysia, 93586 Kuching, Sarawak, Malaysia.

<sup>2</sup>Centre of Paediatric Dentistry and Orthodontics Studies, Faculty of Dentistry, Universiti Teknologi MARA, 47000 Sungai Buloh Campus, Selangor, Malaysia.

## **Correspondence:**

Rohaida Abdul Halim,  
Centre of Paediatric Dentistry and Orthodontics Studies,  
Faculty of Dentistry,  
Universiti Teknologi MARA,  
Sungai Buloh Campus,  
47000 Selangor, Malaysia  
Email: dr\_rohaida@uitm.edu.my

## **Abstract**

It is known that managing patients with dental fear and anxiety is challenging for clinicians and patients. This series of case reports highlights the importance and benefits of dental management under clinical hypnosis as an adjunct to nitrous oxide inhalation sedation for ages six to fifteen. These treatments range from pulp therapy, extraction and minor oral surgery. Customised hypnosis scripts were utilised for each patient, and the metaphors used were tailored to the patient's interest and preference. The intended treatment was successfully carried out in all the patients. Five cases discussed in this case series were initially indicated for treatment under general anaesthesia, but treatment was successfully carried out using hypnosis and nitrous oxide/oxygen sedation. In the two surgical cases, nitrous oxide was tapered off once local anaesthesia was achieved, and the state of relaxation was maintained using a hypnotic trance, reducing the anaesthetic agent's utilisation. Hypnosis successfully reduces patients' anxiety, allowing them to feel more relaxed and confident about accepting future dental treatment without the need for pharmacological intervention.

**Keywords:** Hypnosis, Dental Anxiety, Nitrous Oxide, Children

## **Introduction**

Dental treatment is often challenging for both the patient and dental practitioner. This could be due to multiple factors, such as the child's age and cognitive level, direct or indirect traumatic past dental and/or medical experiences, or the number and/or complexity of the treatment provided (1). As a colourless, odourless, sweet-smelling inorganic gas, nitrous oxide is known for its anxiolytic properties. It can help children feel more relaxed and less anxious during dental procedures, improving their overall experience (2). When used appropriately, nitrous oxide and oxygen therapy are considered safe and effective for managing pain and anxiety in dentistry (3). It is an effective calming relaxation drug commonly referred to as an anxiolytic agent (4). Nitrous oxide can raise the patient's pain threshold. This means it can enhance the effectiveness of local anaesthetic agents used during dental procedures, further reducing pain and discomfort (3, 4).

Nitrous oxide and oxygen inhalation therapy, commonly known as "laughing gas", has various applications in dentistry, especially for certain children. However, as

Ashley et al. reported, some limitations are associated with its use (5). Nitrous oxide may not be highly efficacious on its own. It is often used with other behaviour management techniques, such as "tell, show, do" and positive reinforcement. Successful administration of nitrous oxide and oxygen requires the patient to have clear nasal passages, be willing to wear the nasal mask, and breathe through the nostrils. Not all children may be comfortable with these requirements, and compliance can be a challenge, particularly for younger or anxious patients (2, 4). The use of a nasal mask for nitrous oxide delivery may interfere with local anaesthesia, especially for procedures involving infiltration of the maxillary anterior teeth. This interference may make it difficult for dentists to administer local anaesthetics (5). This suggests that its effectiveness relies on a multifaceted approach rather than being a standalone solution for all cases. While nitrous oxide and oxygen inhalation therapy can be a valuable tool in paediatric dentistry, its limitations necessitate a careful assessment of each patient's needs and preferences.

Nitrous oxide can induce subjective effects, such as feeling light and dissociated. These effects can be reinforced

by hypnotic suggestion, creating a more relaxed and comfortable experience for the patient (4). Hypnosis is defined as an altered state of consciousness supported by neurophysiological changes. It is distinct from meditative states and states of relaxation (6). Hypnosis has various applications in dentistry, including: 1) adjunct anxiolytic agent: it can be used as an adjunct to reduce anxiety during minor oral surgery, 2) pain management: hypnosis can help to reduce the intensity of pain in orofacial and temporomandibular pain, and 3) anxiety reduction and relaxation: hypnosis can alleviate anxiety and promote relaxation in dental patients (7).

Advantages of hypnosis in dentistry include: 1) non-invasive: hypnosis does not require the use of instruments or drugs, making it a non-invasive technique and accessible in various clinical settings, 2) safety: when used in conjunction with nitrous oxide, this method is deemed safe, 3) conscious patient: the patient remains conscious during the procedure, which can be reassuring to some individuals, and 4) non-pharmacological approach: hypnosis is non-pharmacological, so there are no side effects associated with medications, and it does not contribute to environmental pollution (6, 7). These case series aim to emphasise the potential benefits of using clinical hypnosis as an adjunct in managing dentally anxious patients, particularly when combined with nitrous oxide/oxygen inhalation sedation. It offers a holistic approach to dental care that focuses on patient comfort and anxiety reduction while minimising the use of drugs and specialised equipment. However, dental practitioners need to have the necessary training and expertise in hypnosis techniques to ensure its safe and effective use in a dental setting.

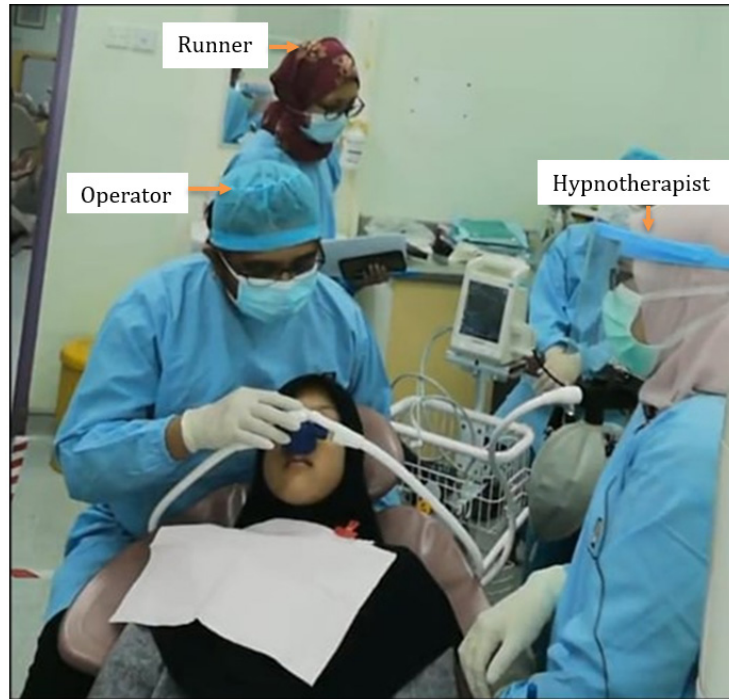**Case presentation**

The following five cases are examples of cases managed under nitrous oxide with hypnosis as an adjunct (Table 1). Informed and written consent was acquired from the parents and all of them agreed and accepted the procedure. Indications of the patients include patients with anxiety, needle phobia, uncooperative patients, and a fear of pain. The hypnosis was performed by a qualified hypnosis paediatric dental specialist (AV and RAH). All cases were done on chairside, and the treatment ranged from the root canal treatment, extraction of a tooth, minor oral surgery of tooth, and surgical repositioning of traumatized teeth. All procedures underwent the complete cycle of hypnosis from introduction, deepener, suggestions, and awakening. Almost majority of the patients were hypnotized for five to thirty minutes. Figure 1 depicts the positions of the operator, the hypnotherapist, and the runner (focus on sedation, patient monitoring, and team coordination) during the nitrous oxide sedation and hypnosis procedure. The hypnotherapist was at touching distance of the patient and allowing for optimal hearing. The environment was peaceful with little distraction/preparation of instruments ready to go and discussion among personnel very minimal to ensure the success of the hypnosis.

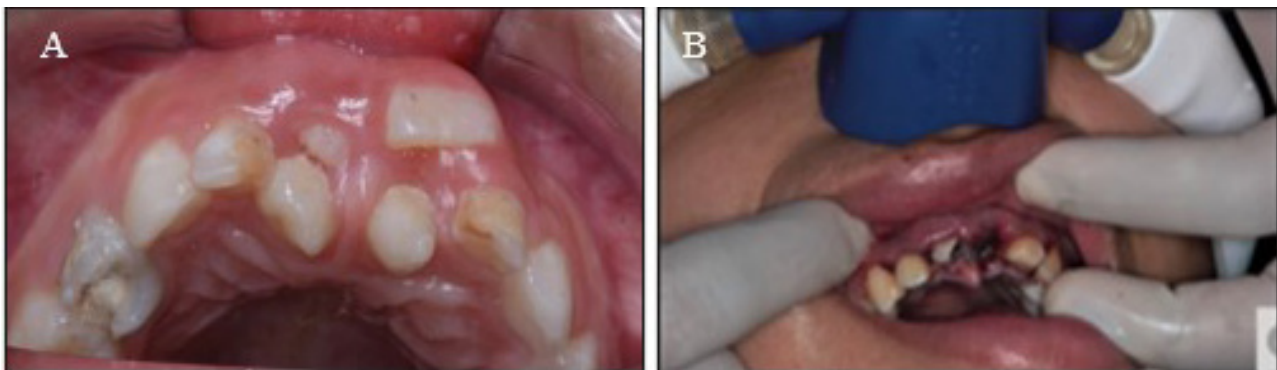
These cases demonstrate the successful integration of nitrous oxide with hypnosis as an adjunct in paediatric dentistry to manage anxious or uncooperative patients. The use of qualified specialists, a structured approach to hypnosis, and the range of procedures covered highlight the potential benefits of this combined approach in improving the dental experience for paediatric patients and addressing their specific needs and fear.

**Table 1:** Five cases of the utilisation of hypnosis and nitrous oxide during dental procedures.

Case	Age	Sex	Medical History	GA indication	Dental history	Hypnotic suggestion	Dental Treatment	Induction use	Deepener use
1 (WHT)	6	M	Healthy	Yes	History of failed nitrous oxide sedation	Mobile legend game	Pulpectomy of 75	Simple eye closure	10 to 1 countdown
2 (TB)	9	M	Healthy	Yes	Severe anxiety towards the extraction	K-Pop Song played	Minor oral surgery 46	Simple eye closure	10 to 1 countdown
3 (RH)	8	F	Healthy	Yes	First dental experience	Choose a room with a Frozen song played	Extraction of mesiodens	Simple eye closure	10 to 1 countdown
4 (AM)	11	F	Mild Autism	Yes	Unable to cope with dental treatment	Floating and listening to dynamite song by BTS	Extraction of 36	Simple eye closure	Favourite place of relaxation
5 (QZ)	15	M	Anaemia	Yes	Needle Phobic	Be in the concert	Surgical repositioning of traumatized teeth	Simple eye closure	Favourite place of relaxation



**Figure 1:** Operator, hypnotherapist, and runner setting up position during nitrous oxide with hypnosis procedure



**Figure 2:** (A) Mesiodens on the upper anterior segment; (B) Avulsed tooth 21, intruded 11 with uncomplicated crown fracture, concussion of 12, and uncomplicated crown fracture of 22

**Case 1**

A 6-year-old Chinese boy, WHT, is an otherwise healthy individual with a history of regular dental visits. WHT displayed significant anxiety toward dental treatment. Upon examination, he was diagnosed with early childhood caries and plans for comprehensive dental treatment under general anaesthesia. While waiting for the general anaesthesia session, WHT complained of pain and discomfort related to tooth 75. Tooth 75 was diagnosed with irreversible pulpitis. After discussing the situation with his mother, we decided on an immediate treatment plan that involved pulpectomy of tooth 75 under inhalation sedation coupled with the use of hypnosis techniques. It is worth noting that WHT is a passionate fan of the mobile legend game. To establish rapport and build trust with him, we engaged in a conversation about the game, delving into details about his favourite characters and the stage he was

currently playing. The pulp therapy of tooth 75 proceeded smoothly under inhalation sedation with hypnosis, and WHT displayed remarkable cooperation throughout the treatment, reflecting the effectiveness of this approach in managing dental anxiety.

**Case 2**

A 9-year-old fit and healthy Malay boy had a history of severe anxiety towards dental extraction due to his previous unpleasant experience. The patient presented with a history of recurrence pain and swelling on tooth 46. Tooth 46 was diagnosed with chronic periapical abscess and was indicated for extraction. At the initial stage, the patient quite reluctant to accept the treatment. Hypnotherapy was introduced to the patient with simple eye closure as the induction and 10 to-1 countdowns as the deepener. The patient was a K-pop fan and chose to listen to K-pop songs

while doing the treatment. The patient felt very easy and relaxed and was able to tolerate the minor oral surgery procedure successfully.

### **Case 3**

An 8-year-old Malay girl, presented as a systemically healthy patient but had a documented history of dental abscess, specifically involving tooth 84. She was referred to our specialty clinic by a general dental practitioner for advanced behaviour management and the extraction of tooth 84 due to her evident dental anxiety. Upon clinical assessment, she exhibited the clinical findings of extensive dental caries on teeth 74 and 75, along with a pronounced gingival abscess associated with mesiodens on the upper anterior segment (Figure 2A). Our comprehensive treatment plan encompassed the restorative rehabilitation of teeth 74 and 75 and the extraction of mesiodens. Given the limited scope of sedation modalities, a thorough discussion was undertaken with the full concurrence of the patient parents, ultimately leading to the selection of nitrous oxide inhalation sedation coupled with adjunctive hypnotherapy as the chosen anxiolysis regimen. To facilitate patient rapport and enhance her comfort, we initiated dialogue centered around her cinematic preference, specifically the Frozen franchise. This engagement extended to a detailed exploration of her favourite characters and the movie musical score. The tooth extraction procedure involving mesiodens was executed with precision and ease under the influence of inhalation sedation and hypnosis, eliciting a commendable level of patient cooperation. This outcome serves as a treatment for the efficacy of this tailored approach in mitigating dental anxiety and ensuring successful treatment execution.

### **Case 4**

An 11-year-old Malay girl with underlying mild autism had a history of anxiety and was unable to cope with dental treatment due to a previous unpleasant experience. The patient presented with multiple dental caries and had a history of recurrence pain and swelling on his tooth 36. Tooth 36 was diagnosed with chronic periapical periodontitis and was indicated for extraction. At the initial stage, the patient was quite reluctant to accept the treatment. Hypnotherapy was introduced to the patient with simple eye closure as the induction and favorite place of relaxation as the deepener. The patient was a fan of the BTS K-pop group and chose to be at the BTS concert for her favorite place of relaxation. The patient felt very easy and relaxed during the therapy and the treatment was carried out successfully.

### **Case 5**

A 15-year-old Malay boy with a history of nutritional anemia sustained dental injuries after having a fall from the top of a locker and hitting the side of a metal frame bed. Although he was taken to the emergency immediately after the incident, proper treatment could not be given as the patient was uncooperative. Lack of information and

logistical issues resulted in the patient seeking treatment after 48 hours at our institute. The patient presented with avulsed 21, intruded 11 with uncomplicated crown fracture, concussion of 12 and uncomplicated crown fracture of 22 (Figure 2B). As the patient was extremely anxious, nitrous oxide sedation with adjunct hypnotherapy was used to carry out the surgical repositioning of 11 and splinting. Customized hypnosis scripts were utilized for this patient and the metaphors used were tailored to his interest and preference in this case being in the concert which was his favourite place of relaxation. During the long surgical case, nitrous oxide was tapered off once local anaesthesia was achieved and the state of relaxation was maintained using a hypnotic trance which reduced the utilization of anaesthetic agent.

### **Discussion**

This case series highlights the effectiveness and acceptance of the combination of hypnosis and nitrous oxide inhalation sedation in managing anxious and uncooperative children during dental procedures (8). The combination of these two modalities was found to be an effective approach for managing anxious and uncooperative paediatric patients. This combination likely helped improve the overall dental experience for these children. Despite having little to no prior experience with hypnosis, the patients in the study had positive attitudes toward it. This suggests that hypnosis was well-received and viewed favourably by the young patients.

Using hypnosis with paediatric dental patients is an engaging and effective approach that capitalises on their active imaginations, receptiveness to suggestions, and belief in the possibilities presented to them (7, 8). Paediatric patients do not require the same level of explanation or trance inductions as adults (9). Children are already in a state of hypnosis most of the time due to their active imaginations (10). They readily engage in imaginative play, making this technique effective for children as young as 4 to 12 years old (11). An ethical and trained hypnotherapist, who is skilled at engaging in imaginative play can work effectively with paediatric dental patients. The hypnotherapist understands the heightened state of suggestibility in children and strategically offers therapeutic suggestions when the child is most receptive. Children tend to believe that anything is possible and often accept what adults and authority figures say as true (7, 11). This heightened level of suggestibility makes them particularly responsive to hypnotic suggestions and therapeutic interventions (12). This uniqueness makes working with paediatric dental patients different from working with adults in creating a playful and supportive environment to reduce dental anxiety and enhance the overall dental experience for young patients.

Hypnosis was found to be effective in reducing anxiety in these patients. Dental anxiety is a common concern among children, and finding non-invasive methods to alleviate it can greatly benefit paediatric dental care. The

study suggests that hypnosis is applicable to daily dental care. This implies that hypnosis can be integrated into routine dental procedure, has led to an increase in the patient's pain threshold and improved pain tolerance (9). In these two surgical cases, nitrous oxide was gradually reduced once local anaesthesia had been achieved. This indicates that nitrous oxide, commonly used for its anxiolytic and analgesic properties, was supplemented by hypnosis to maintain relaxation and comfort. However, the greenhouse effect that nitrous oxide has on global warming makes it detrimental to the ecosystem as well (9, 12). For self-administered administration, there are no scavenging systems, therefore the stored nitrous oxide will also be harmful to the staff members who operate in the closed room all the time (11, 12). Deficit of Vitamin B12 in myelinoses leading to subacute degeneration of the spinal cord is one of the long-term side effects that has been frequently reported (9, 11).

The use of hypnosis in maintaining a relaxed state allowed for a reduction in the utilisation of the anaesthetic agent. This is significant because it could help minimise potential side effects or complications associated with anaesthetic agents while ensuring patient comfort.

As described earlier, the use of hypnosis in conjunction with nitrous oxide inhalation sedation in dental procedures offers several advantages. One of the notable benefits is the reduction in the utilisation of anaesthetic agents. This can lead to a decreased need for sedative and analgesic medications, which is advantageous for patient safety and comfort (13). In cases where patients were initially indicated for treatment under general anaesthesia due to high anxiety levels, the combination of hypnosis and nitrous oxide inhalation sedation allowed for successful treatment without the need for general anaesthesia. This is especially valuable when there are limited slots for general anaesthesia (14). The use of hypnosis, together with nitrous oxide, not only achieves effective physiological sedation but also effectively addresses anxiety. This combination allows the patient to remain cooperative and responsive during the procedure while minimising the need for additional sedation or analgesic agents (6, 8).

In this study, hypnosis was found to have beneficial effects on behaviour management during the administration of local anaesthesia and tooth extraction in children aged 6 to 15 years old. This suggests that hypnosis can be a valuable tool in promoting cooperation and managing anxiety in this age group. None of the cases reported any adverse effects following the induction of hypnosis. This indicates that the children were willing to accept and be open to suggestions during the hypnotic trance. The absence of adverse effects is a positive sign of the feasibility and safety of using hypnosis in this context.

If patient exhibits resistance or rejection of hypnosis, it may be necessary for the clinician to consider alternative techniques that the patient is more receptive to (9). Patient acceptance and cooperation are essential for the success of hypnosis as an adjunct therapy (13). However, changing

the technique or delaying the implementation of hypnosis can have adverse effects on patient acceptance. Prolonged efforts or postponements may reduce patient's willingness to engage in hypnosis effectively (15). Therefore, it is crucial for clinicians to be adept at recognising when to introduce hypnosis into the treatment process (14, 15).

Apart from that, patient selection criteria to ensure a successful combined technique and the training required for the hypnotherapist are crucial for the success of the dental procedure (14, 15). Indications for the combined technique include patients who cannot receive conventional treatment, those with ASA I and stable ASA II, and those with ASA III or higher, who should be referred to anaesthetists for further assessment of conscious sedation (15). Practitioners must be skilled in providing procedural hypnosis, gaining advanced skills in airway control and cardiovascular support, performing patient monitoring, and managing all potential complications (14). Monitoring, which entails observing, measuring, and recording physiological indicators, is critical to ensuring the patient's well-being (12, 15). Furthermore, as presented in this case series, the benefits of having an extra dentist who is qualified to perform hypnosis and join in on the dental procedure include assisting during the procedure as well as understanding and providing the hypnosis script in accordance with the dental treatment delivered.

This study had some limitations, which are important to be acknowledged for future research and practice improvement. The study did not use standardised assessment criteria, such as a phobia questionnaire, to objectively assess the level of dental anxiety in patients before treatment. Relying solely on patient self-reporting during interviews may lead to subjectivity and potentially miss cases of severe dental anxiety. Using validated assessment tools could provide more accurate baseline data. Apart from that, this study did not employ equipment or apparatus to monitor the patient's physical responses, such as blood pressure and heart rate, during the dental procedure. Physiological monitoring can offer valuable insights into the patient's stress response and the effectiveness of hypnosis in achieving relaxation. In addition, there is a lack of post-op questionnaires to assess the patient's level of anxiety and their overall experience during the dental visit. Such questionnaires can provide valuable feedback on the effectiveness of the intervention and patient satisfaction. By addressing these limitations and adopting a more comprehensive approach to research and practice, it may be possible to further enhance the effectiveness of hypnosis as adjunctive therapy for managing dental anxiety in paediatric patients and improve the overall quality of care.

## **Conclusion**

In conclusion, the combination of hypnosis and nitrous oxide inhalation sedation offers a valuable alternative to general anaesthesia in managing highly anxious paediatric dental patients. It not only reduces the need for anaesthetic agents but also promotes effective sedation, patient

cooperation, and anxiety reduction, resulting in a more patient-centred and holistic approach to dental care. However, it requires a skilled hypnotherapist who can create a playful and supportive environment to reduce dental anxiety and enhance the overall experience for these patients.

### **Acknowledgment**

We thank all patients who participated in the study. We also would like to thank the Director General of Health Malaysia for his permission to publish this article.

### **Competing interests**

The authors declare that they have no competing interests.

### **Informed consent**

Written informed consent was obtained from the parents for the publication of this case series.

### **Financial support**

No funding was received for this work.

### **References**

1. Arabzade Moghadam S, Yousefi F, Saad S. The effect of hypnosis on pain relief due to injection of dental infiltration anesthesia. *Clin Exp Dent Res*. 2021; 7(3):399-405.
2. Ashley PF, Chaudhary M, Lourenço-Matharu L. Sedation of children undergoing dental treatment. *Cochrane Database Syst Rev*. 2018; 12(12):CD003877.
3. Dilmahomed H, Jovani-Sancho M. Hypnoanalgesia in Dentistry: A Literature Review. *Am J Clin Hypn*. 2019; 61(3):258-275.
4. Ibrahim DFA, Hussein AS, Hamzah SH. Nitrous Oxide Inhalation Sedation in Pediatric Dentistry: An overview of the available guidelines. *Jordan Med J*. 2022; 56(2):159-169.
5. Johnson AJ, Elkins GR. Effects of Music and Relaxation Suggestions on Experimental Pain. *Int J Clin Exp Hypn*. 2020; 68(2):225-245.
6. Khinda V, Rao D, Sodhi SPS. Nitrous Oxide Inhalation Sedation Rapid Analgesia in Dentistry: An Overview of Technique, Objectives, Indications, Advantages, Monitoring, and Safety Profile. *Int J Clin Pediatr Dent*. 2023; 16(1):131-138.
7. De Stefano R. Psychological Factors in Dental Patient Care: Odontophobia. *Medicina (Kaunas)*. 2019; 55(10):678.
8. Monteiro J, Tanday A, Ashley PF, Parekh S, Alamri H. Interventions for increasing acceptance of local anaesthetic in children and adolescents having dental treatment. *Cochrane Database Syst Rev*. 2020; 2(2):CD011024.
9. Passos De Luca M, Massignan C, Bolan M, Butini Oliveira L, Aydinoz S, Dick B et al. Does the presence of parents in the dental operatory room influence children's behaviour, anxiety and fear during their dental treatment? A systematic review. *Int J Paediatr Dent*. 2021; 31(3):318-336.
10. Rienhoff S, Splieth CH, Veerkamp JSJ, et al. Hypnosis and Sedation for Anxious Children Undergoing Dental Treatment: A Retrospective Practice-Based Longitudinal Study. *Children (Basel)*. 2022; 9(5):611.
11. Silva JJ, Da Silva J, Souza LF, et al. Effectiveness of hypnosis on pain and anxiety in dentistry: Narrative review. *Am J Clin Hypn*. 2022; 65(2):87-98.
12. Tieri M, Cosi A, Lombardi L, et al. Nitrous oxide and hypnotherapy in paediatric dentistry. *Eur J Paediatr Dent*. 2023; 24(3):229-237. doi:10.23804/ejpd.2023.1932
13. Venkiteswaran A, Tandon S. Role of Hypnosis in Dental Treatment: A Narrative Review. *J Int Soc Prev Community Dent*. 2021; 11(2):115-124.
14. Wolf TG, Schläppi S, Benz CI, Campus G. Efficacy of Hypnosis on Dental Anxiety and Phobia: A Systematic Review and Meta-Analysis. *Brain Sci*. 2022; 12(5):521.
15. Wolf TG, Wolf D, Below D, d'Hoedt B, Willershausen B, Daubländer M. Effectiveness of Self-Hypnosis on the Relief of Experimental Dental Pain: A Randomized Trial. *Int J Clin Exp Hypn*. 2016; 64(2):187-199.