

# RUPTURE OF THE CAECUM DUE TO INVASIVE AMOEBIASIS

Rohela Mahmud, Amir Lee<sup>1</sup>, Khairul Anuar, Zurainee Mohd Noor and Johari Surin

Department of Parasitology, Faculty of Medicine, University of Malaya, 50603 Kuala Lumpur, Malaysia, <sup>1</sup>Klinik & Surgeri Semenyih, Selangor, Malaysia

**ABSTRACT:** This paper describes a case of invasive amoebiasis in a 72 year old woman. About 1 week prior to admission she had right iliac fossa pain and physical examination suggested perforated appendix or carcinoma of caecum. Laparotomy revealed perforation of caecum. Histopathology of tissue removed showed abundant trophozoites of *Entamoeba histolytica*. After surgery treatment was instituted and patient had an uneventful recovery. (JUMMEC 2000; 1: 51-52)

**KEYWORDS:** Rupture of caecum, amoebiasis

## Introduction

Amoebiasis is more commonly seen in tropical and subtropical regions and is endemic in Malaysia. Amoebiasis is due to invasion of the colonic mucosa by the enteric protozoan *Entamoeba histolytica*. *Entamoeba histolytica* usually lives as a harmless commensal in the lumen of the human large bowel. Occasionally *E. histolytica* becomes a pathogen. Amoebae invade the tissues by secreting lytic enzymes (6) and through the activation of the complement system. This lytic and pseudopodial activities of the amoebae is the major cause of its penetration and necrotising activity in the tissues. In rare instances, they invade the muscle layers and further outward invasion of tissues results in perforation of the gut. Immune suppression due to any cause, and other bowel infections favour this invasion. Precipitating causes for perforation eg. parturition, external trauma and surgery have been mentioned (6). Perforation of the colon is a rare but frequently fatal complication of amoebiasis (2). Owing to varying presentations, the condition is often not diagnosed preoperatively (2).

## Case report

The patient, a 72 year old Chinese woman complained of right iliac fossa pain of one week duration. One month previously she had experienced a few episodes of bloody diarrhea. Examination revealed a febrile patient with a temperature of 38 °C. Abdomen was tender at right iliac fossa with a mass. A presumptive diagnosis was made as perforated appendix or carcinoma of caecum. A laparotomy was done with right paramedial incision. Omentum was found to have a flimsy adhesion on separation.

There was faecal discharge coming from a 3 cm perforation at anterior surface of caecum. Examination of

appendix, liver and other organs appeared normal. Right hemicolectomy was done. The specimen consisting of caecum, appendix and ileum was sent to the Pathology laboratory for gross and microscopic examinations. For microscopic examination sections of tissues removed were submitted in blocks. Sections of 5 – 6 µm were made and stained with hematoxylin and eosin. Patient's blood was taken and sent to the Department of Parasitology for serological test for amoebiasis. ELISA was performed on the patient's serum.

## Direct ELISA

Antigen : *Entamoeba histolytica* in house antigen was used.

Test procedure: Plate was coated with antigen, 50 µl/well. A flex plate bottom was used. Plate was incubated in wet chamber overnight at 4 °C. It was then washed off 3 times with PBS-tween, 5 minutes in between each wash. It was then blocked with 0.5% BSA, 200 µl/well. Plate was covered with aluminium foil and incubated at Room temperature for 2 hours. It was then washed off 3 times with PBS-tween. Serial dilutions of patient's sera were added to the antigen wells, 50 µl / well. Dilutions were made both for IgM and IgG. Antigen and serum dilutions were incubated for 1 hour at room temperature. Excess seen were washed off 3 times with PBS-tween. After being dried the antigen wells were covered with antihuman sera, 50 µl/well and were incubated for 1 hour at Room temperature. After excess antihuman sera had been washed 3 times with PBS – tween, substrate [(PNPP (P-Nitrophenyl Phosphate Tablets) dissolved in 5 ml of DEA (Diethyl amine))] was added to the wells, 50

Corresponding address:  
Associate Prof Rohela Mahmud  
Dept. of Parasitology,  
University of Malaya Medical Centre,  
50603 Kuala Lumpur, Malaysia.

$\mu$ l/ well and incubated for 15 minutes at room temperature. Then the plate was read using the ELISA machine using a 405 filter. A titre of 1:64 was considered positive.

## Results

Gross appearance of specimen is as seen in Figure 1 which shows caecum together with attached terminal part of ileum and appendix. There was an area of friable necrotic perforation of the caecal wall. The site of perforation was covered over the serosa surface by adherent omental fat. The caecal wall including the mucosa around it was oedematous and congested in appearance.

Microscopic examination of the caecum is as depicted in Figure 2. The caecal specimen shows a cluster of trophozoites of *E. histolytica* densely infiltrated by acute inflammatory cells and fibrinous debris. The trophozoites have a tiny, eccentrically located nucleus. Some trophozoites contain erythrocytes.

## Serological test

The serum was positive for both IgM and IgG. IgG is positive with a titre of 1:2048.

## Discussion

Clinical presentation of amoebic colitis is vague and hence the condition is likely to be mistaken for other common abdominal ailments. If the diagnosis is missed, the condition may lead to high mortality rates. Treated in time, it is a curable disease. In the case presented, diagnosis of amoebiasis was missed. The diagnosis could have been made preoperatively in this patient who presented with an acute abdomen and with a history of bloody diarrhoea but it had not been considered. The involvement was primarily caecal and the symptoms mimic ruptured appendicitis or ruptured carcinoma of caecum. Early diagnosis by modern serological tests and prompt treatment with effective anti-amoebic drugs, can prevent complications(6). Therefore it is pertinent for physicians to carry out serodiagnosis for amoebiasis to establish or exclude the diagnosis in patients who present with bloody diarrhoea. For this patient, after the operation she was put on treatment with metronidazole and she had an uneventful recovery.

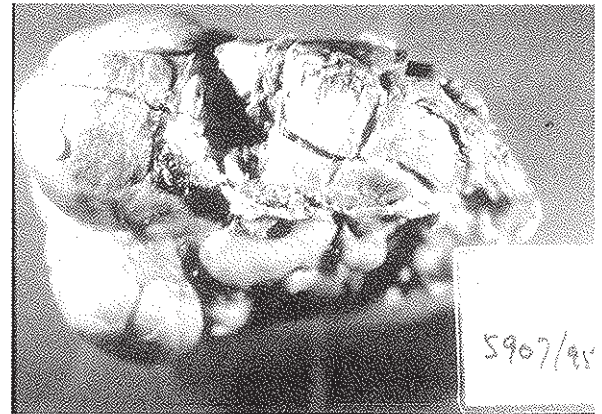


Figure 1. Caecum: necrotic with perforation.

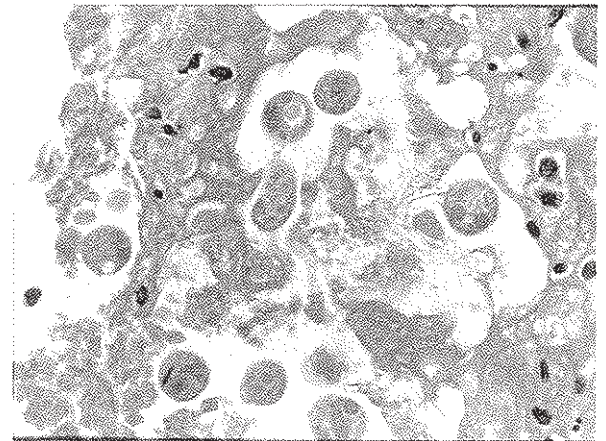


Figure 2. Microscopic appearance showing clusters of trophozoite of *E. histolytica*.

## References

1. Adams EB and MacLeod IN. Invasive amebiasis. I. Amebic dysentery and its complications. *Medicine*, 1977; 56: 315-23.
2. Eggleston FC, Verghese M and Handa AK. Amoebic perforation of the bowel: experience with 26 cases. *Brit. J. Surg.* 1978; 65: 748-51.
3. Harries J. Amoebiasis: a review. *Journal of the Royal Society of Medicine* 1982; 75: 190-7.
4. Judy KL. Amoebiasis presenting as an acute abdomen *Am Jof Surg*, 1974; 127: 275-9.
5. Manukaran MN, Ahmad H and Abdullah I. Amoebiasis with multiple colonic perforations and ruptured liver abscess *Med. J. Malaysia* 1983; 38: 71-3.
6. Thuse MG. Fatal intestinal amoebiasis. *Postgrad. Med. J.* 1979; 55: 548-52.